

## Neurological Assessment

36 Cord and Spinal Nerve Lesions / DTRs /  
Dermatomes

David Trigg, MD

1

---

---

---

---

---

---

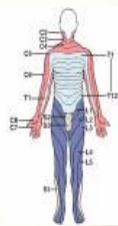
---

---

## Spinal Nerves

Dermatomes

- Landmarks:
  - T 4
  - T 10
- Road rage:
  - C 7
- Shingles  
(Varicella Zoster)



2

---

---

---

---

---

---

---

---

## Herniated Disc

Herniated disc

- Proximity of disc to  
the spinal nerve

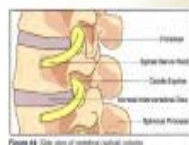


Figure 44-10 Side view of vertebral column

3

---

---

---

---

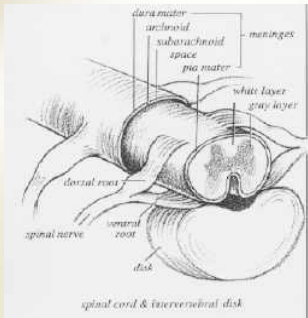
---

---

---

---

## Spinal Nerves in Relation to Vertebral Bodies



4

---

---

---

---

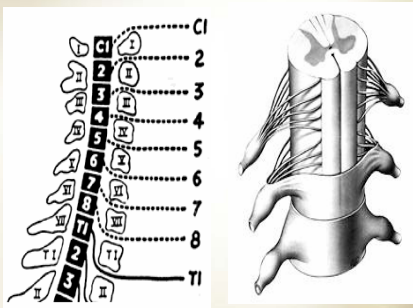
---

---

---

---

## Spinal Nerves in Relation to Vertebral Bodies



5

---

---

---

---

---

---

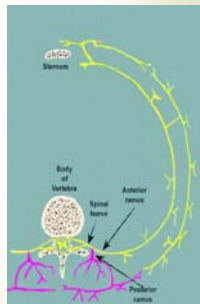
---

---

## Spinal Nerves in Relation to Vertebral Bodies

### Dermatome Anatomy

- Sensory
- Motor



6

---

---

---

---

---

---

---

---



### C-5 Biceps

(and see spinal lesion handout)





7

---

---

---


---

---

---



---


---



### C-6 Wrist Extension

(and see spinal lesion handout)





8

---

---

---

---

---

---

---

---



### C-6 Radial Nerve

(and see spinal lesion handout)





9

---

---

---

---

---

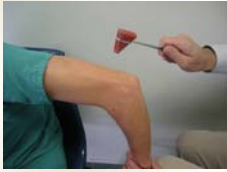---

---

---

## C-7 Triceps

(and see spinal lesion handout)



10

---

---

---

---

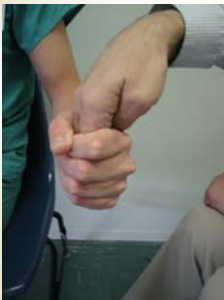---

---

---

---

## C-8 / Median Finger Flexion



11

---

---

---

---

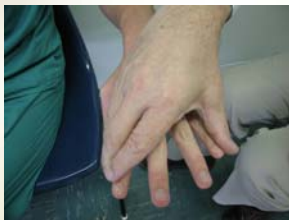---

---

---

---

## T-1 / Ulnar Finger Abduction



12

---

---

---

---

---

---

---

---



### L-4 Patellar Reflex

(and see spinal lesion handout)





13

---

---

---


---

---

---

---


---



### S-1 Plantar Flexion

(and see spinal lesion handout)





14

---

---

---


---

---

---


---

---



See link below for more spinal nerve injury patterns

[Neurological Level Chart](#)



15

---

---

---

---

---

---

---

---



## Further Thoughts

Bates pp.

More to follow



16

---

---

---

---

---

---

---